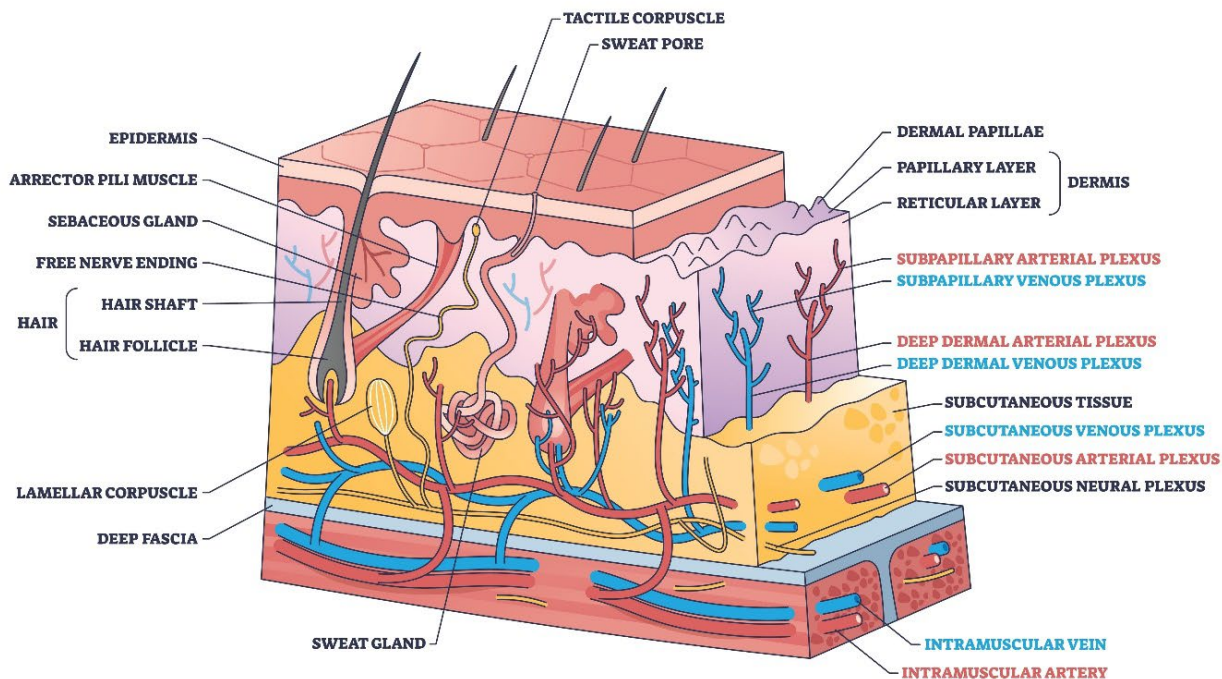


INTEGUMENTARY SYSTEM



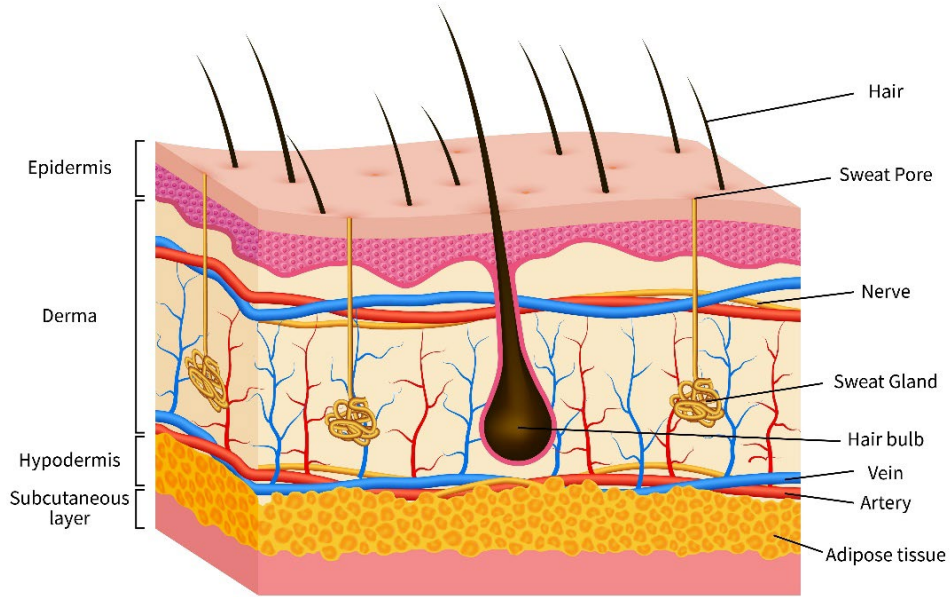
The Integumentary System is the body's largest organ system, encompassing the skin, hair, nails, and associated glands. Its primary functions are protection, sensation, regulation, and secretion. The skin serves as a barrier against pathogens, UV radiation and physical trauma, while also helping to regulate our body temperature.

This visual representation is meant to aid in your studies for the CPC exam. This is supplemental only.

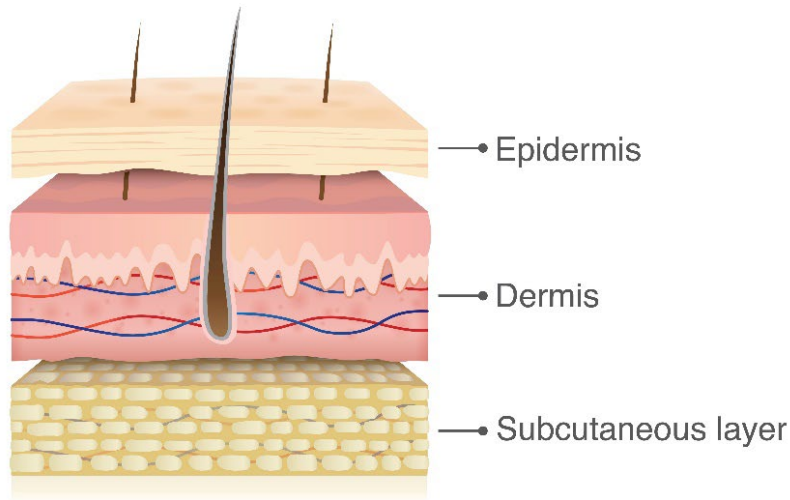
This is in no way an exhaustive list. It is not in order of the CPT or the ICD-10-CM.

For more resources like this, please visit our website at:
www.medicalbillco.com/resources

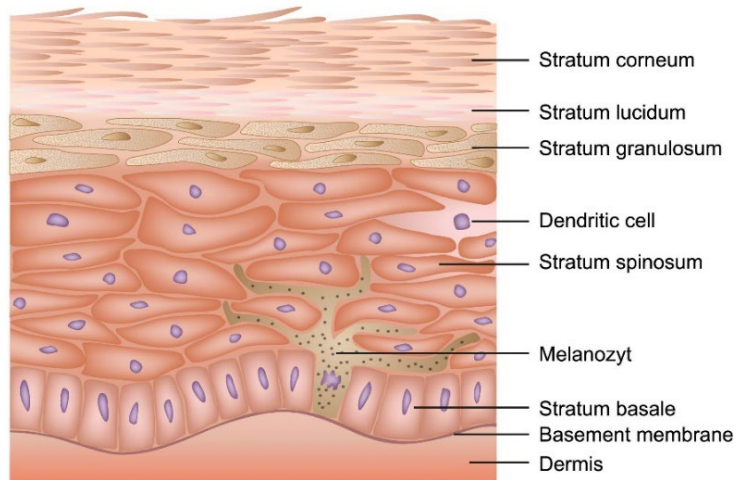
SKIN ANATOMY



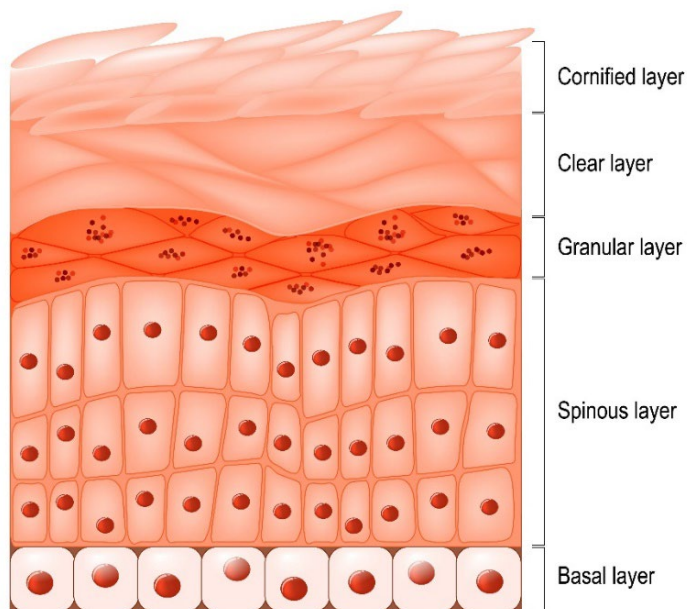
Three Main Layers of The Skin

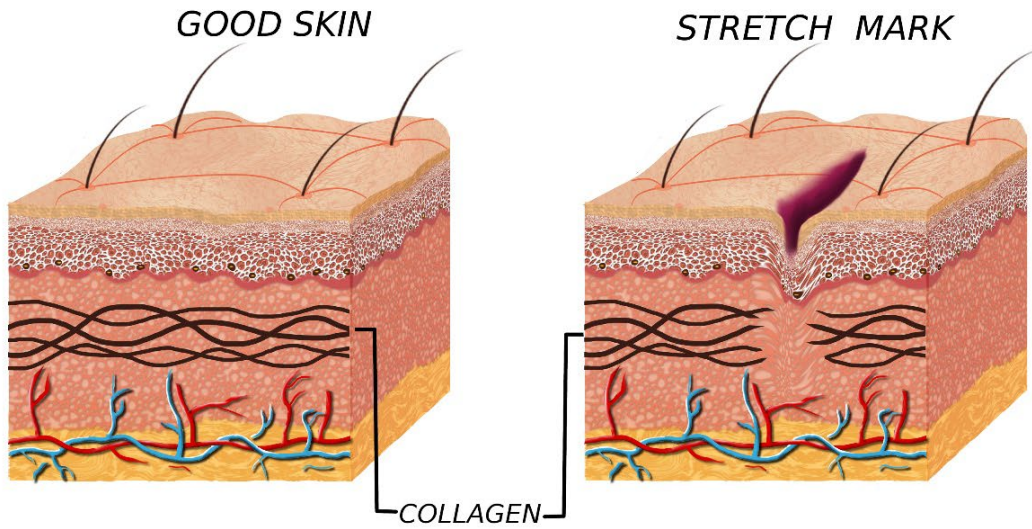


Structure of the Epidermis

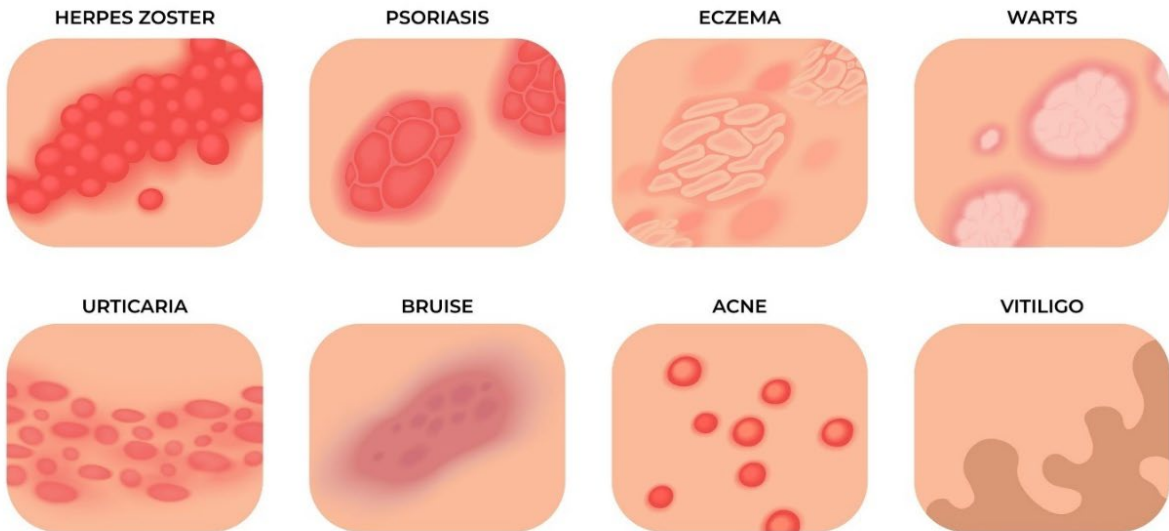


LAYERS OF EPIDERMIS

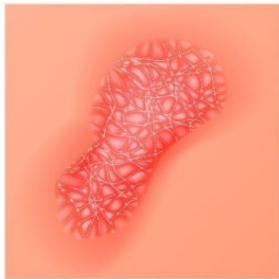



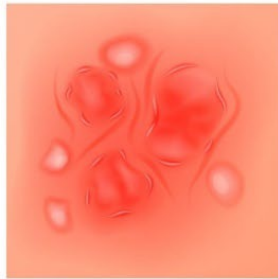
SKIN DISEASES




DISEASES OF THE SKIN



psoriasis



eczema




urticaria



lichen planus



pityriasis versicolor




vitiligo

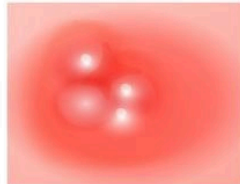

acne

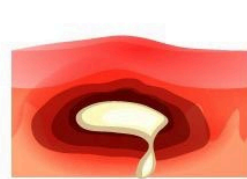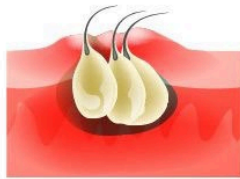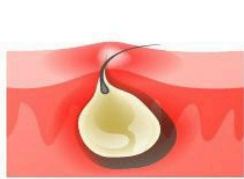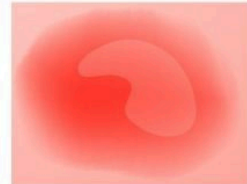
furuncle



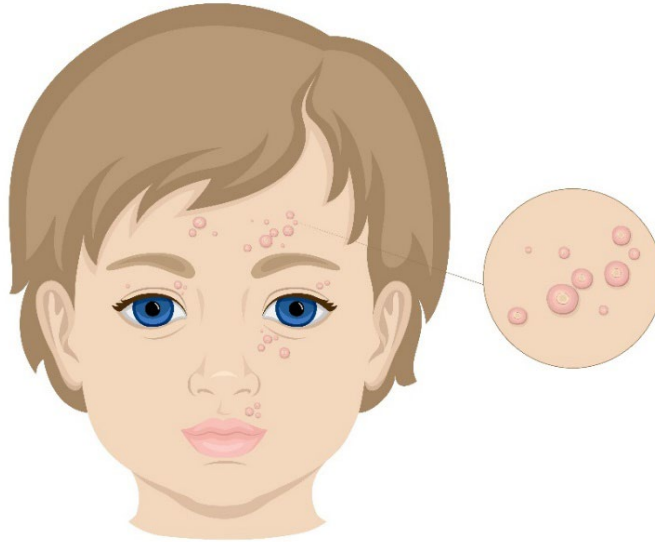
carbuncle



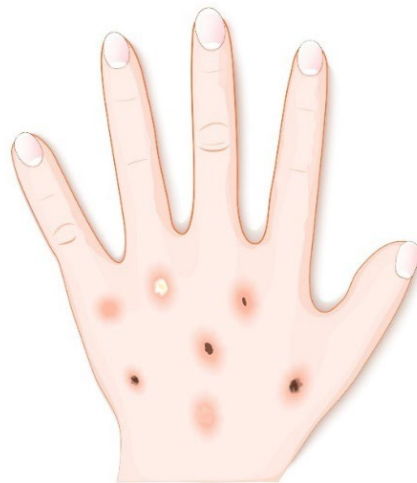phlegmon



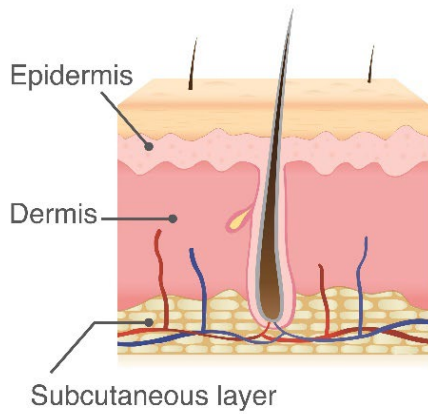
Molluscum contagiosum (water warts)



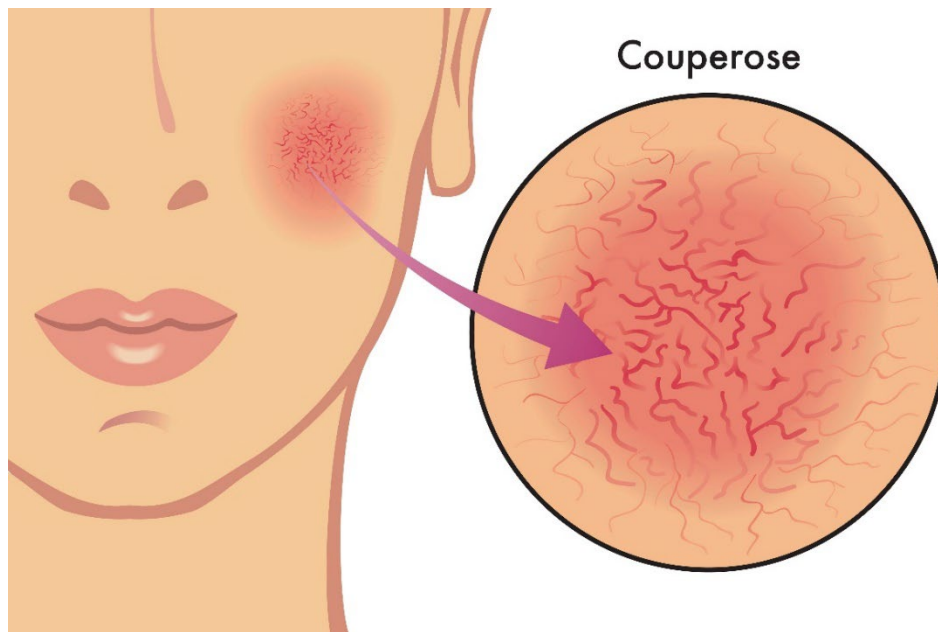
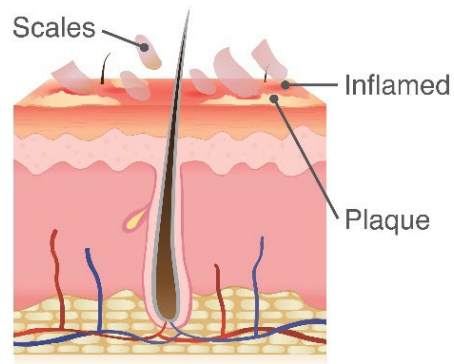
Actinic keratosis (solar keratosis)



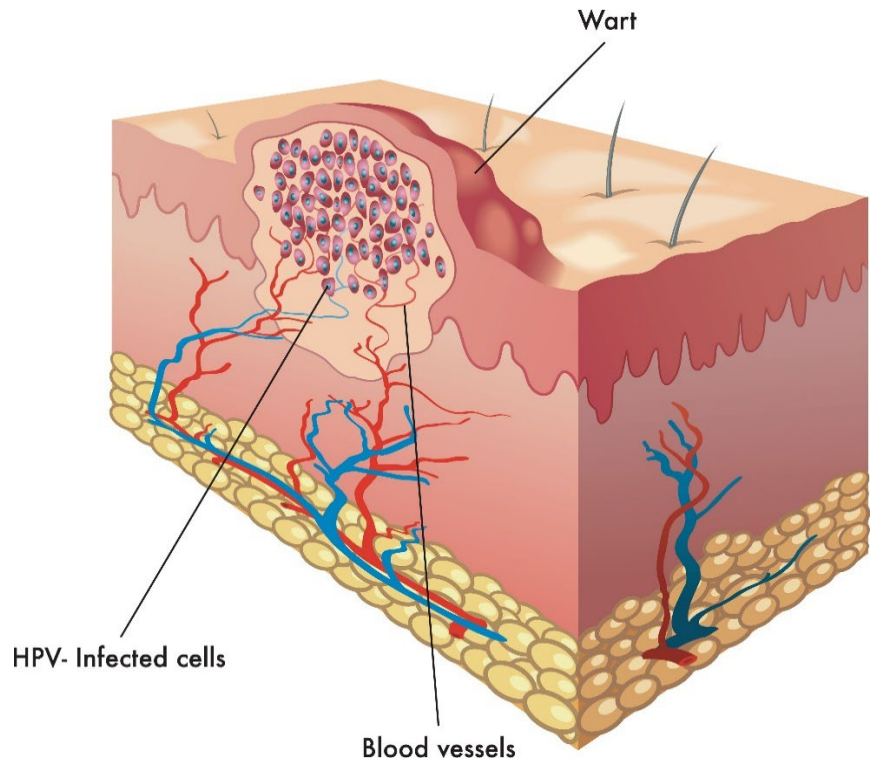
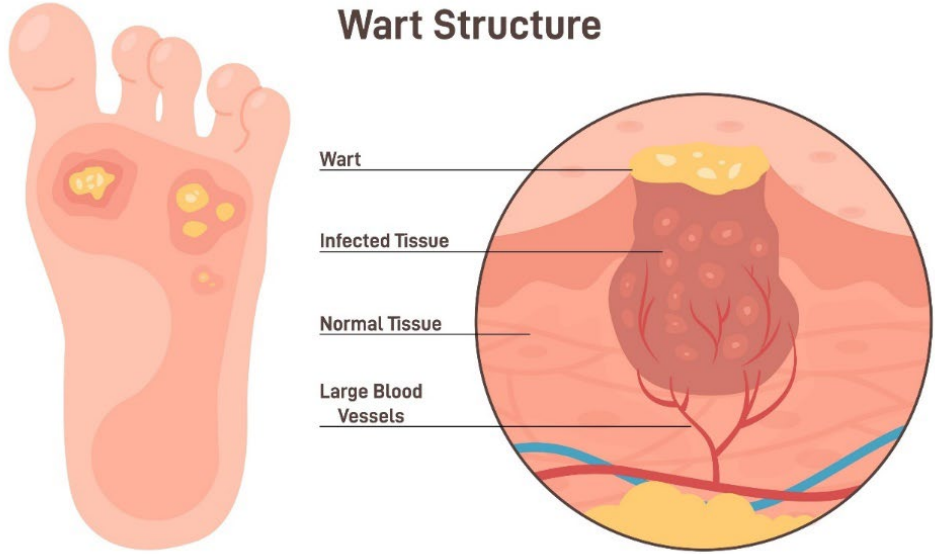
Normal Skin



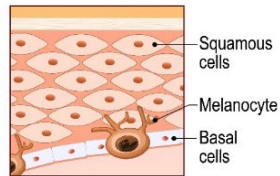
Psoriasis



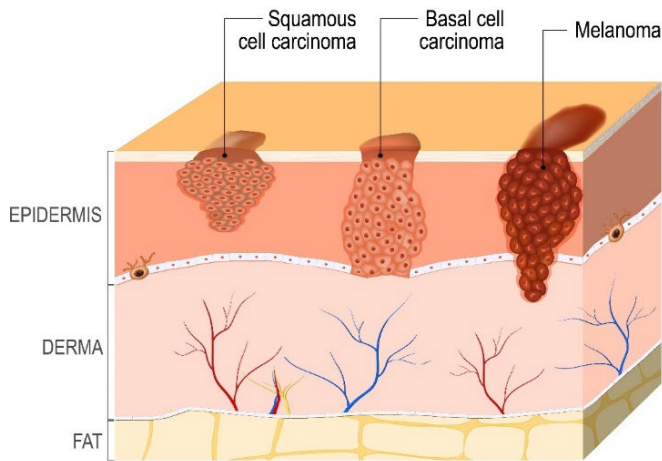
Wart Structure



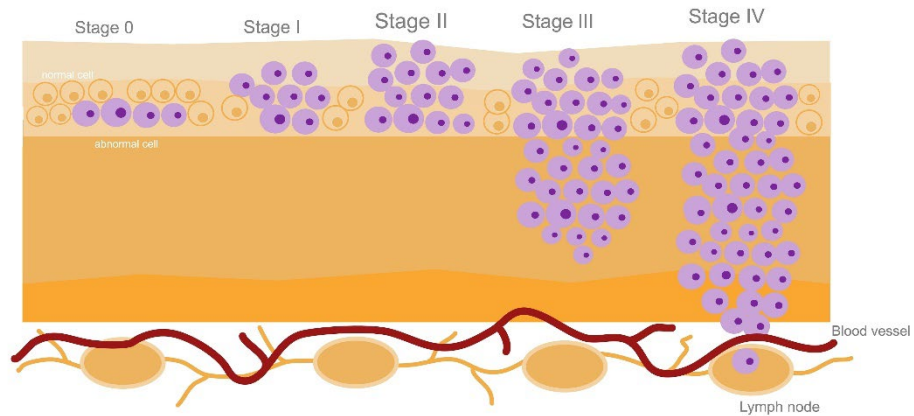
HEALTHY EPIDERMIS



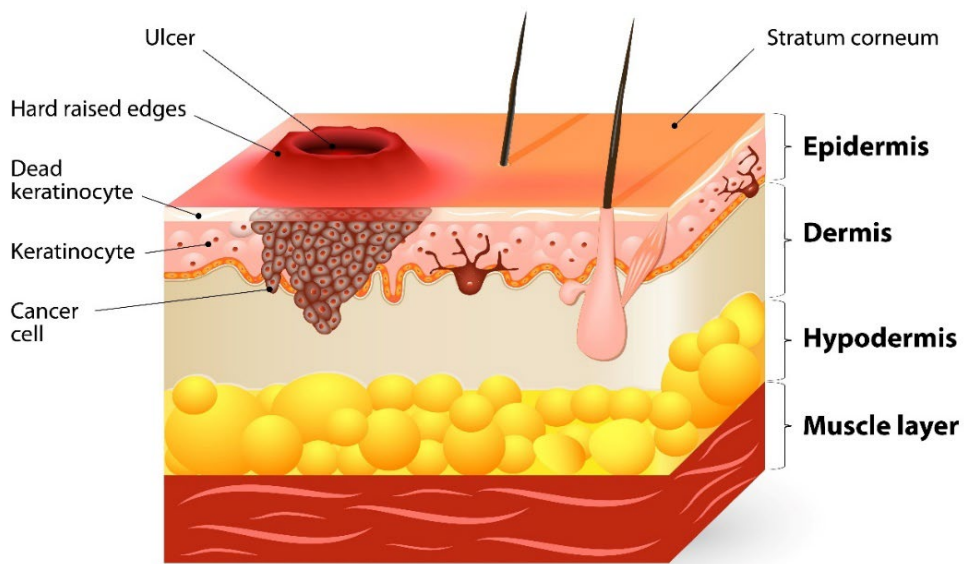
SKIN CANCER



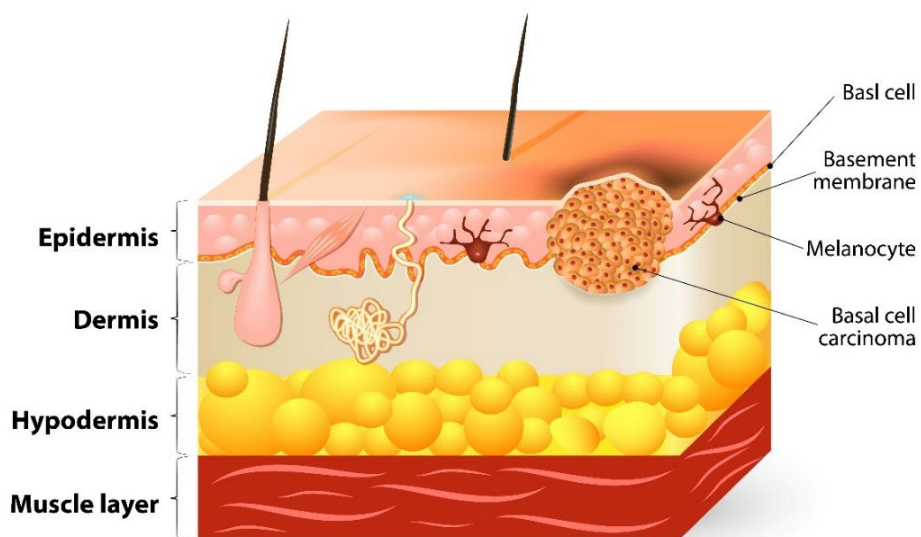
Cancer stage



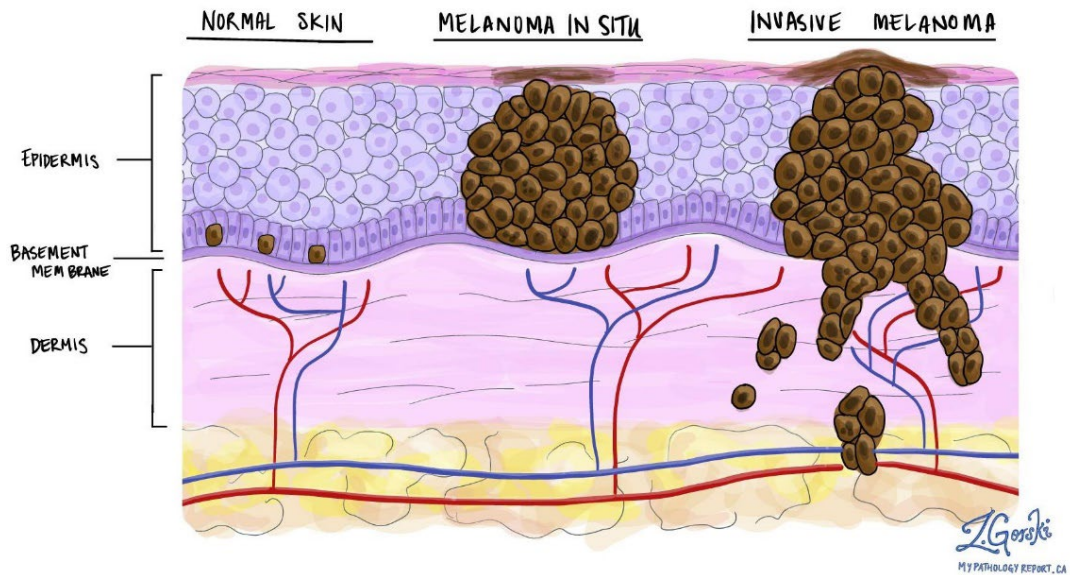
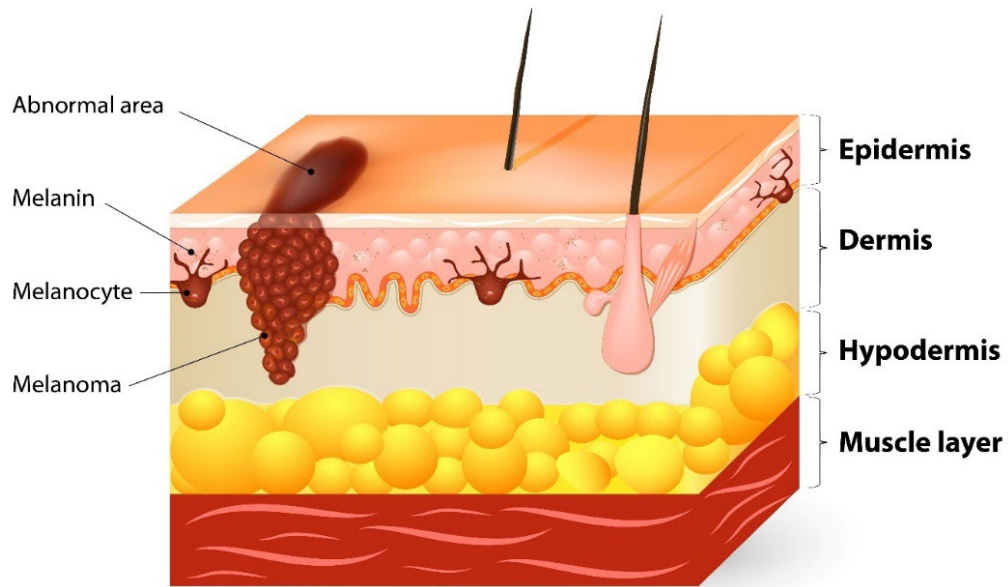
Squamous-cell carcinoma



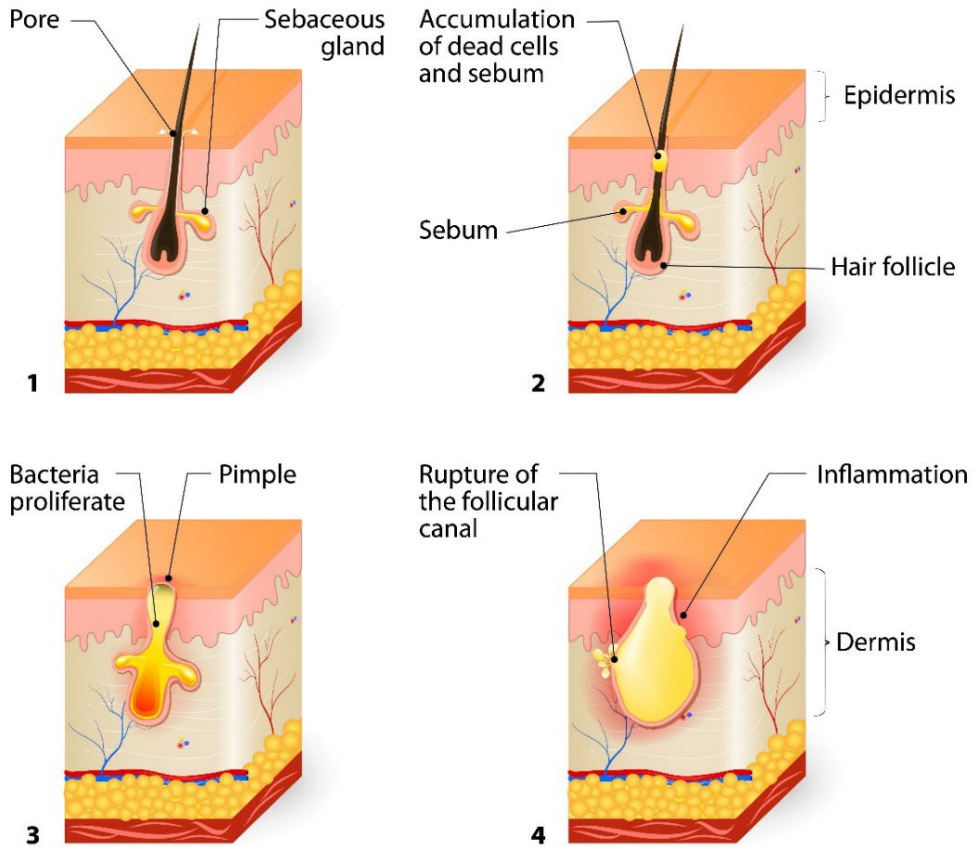
BASAL-CELL CARCINOMA



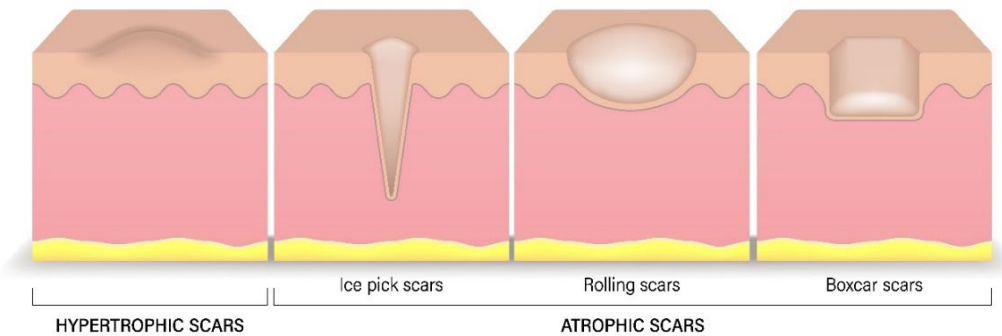
MELANOMA

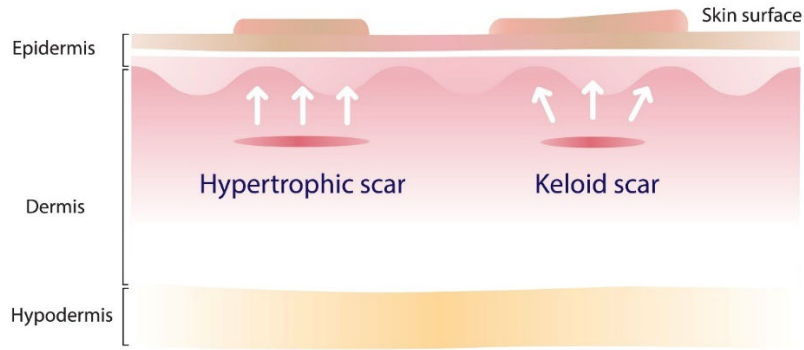


ACNE FORMATION



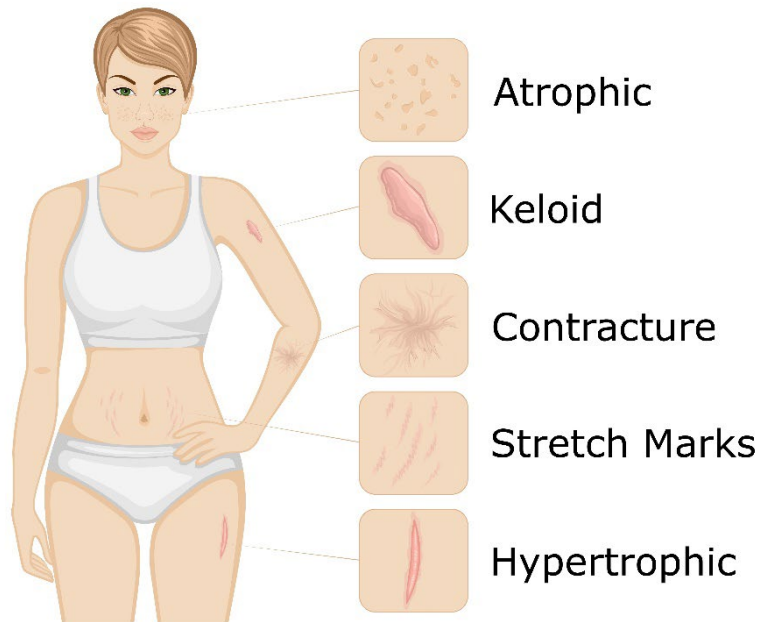
Types of acne scars



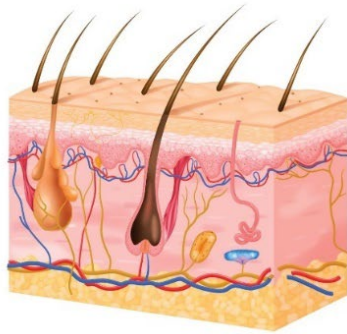


Types of scar

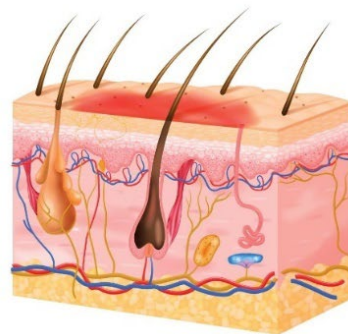
Types of scars



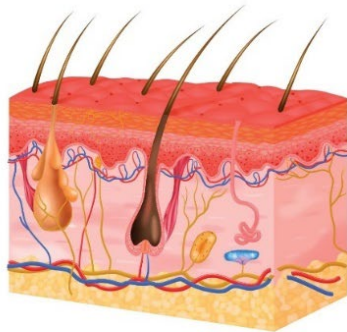
SKIN BURNS



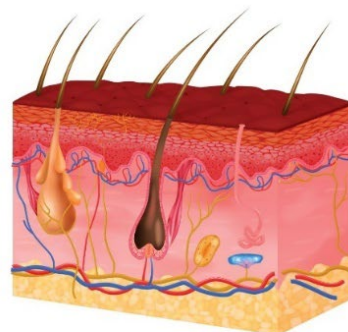
Normal healthy skin



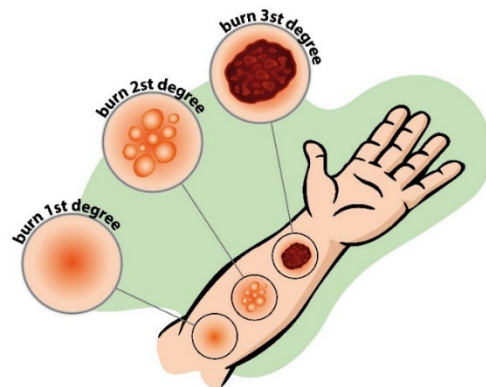
First degree burn injury

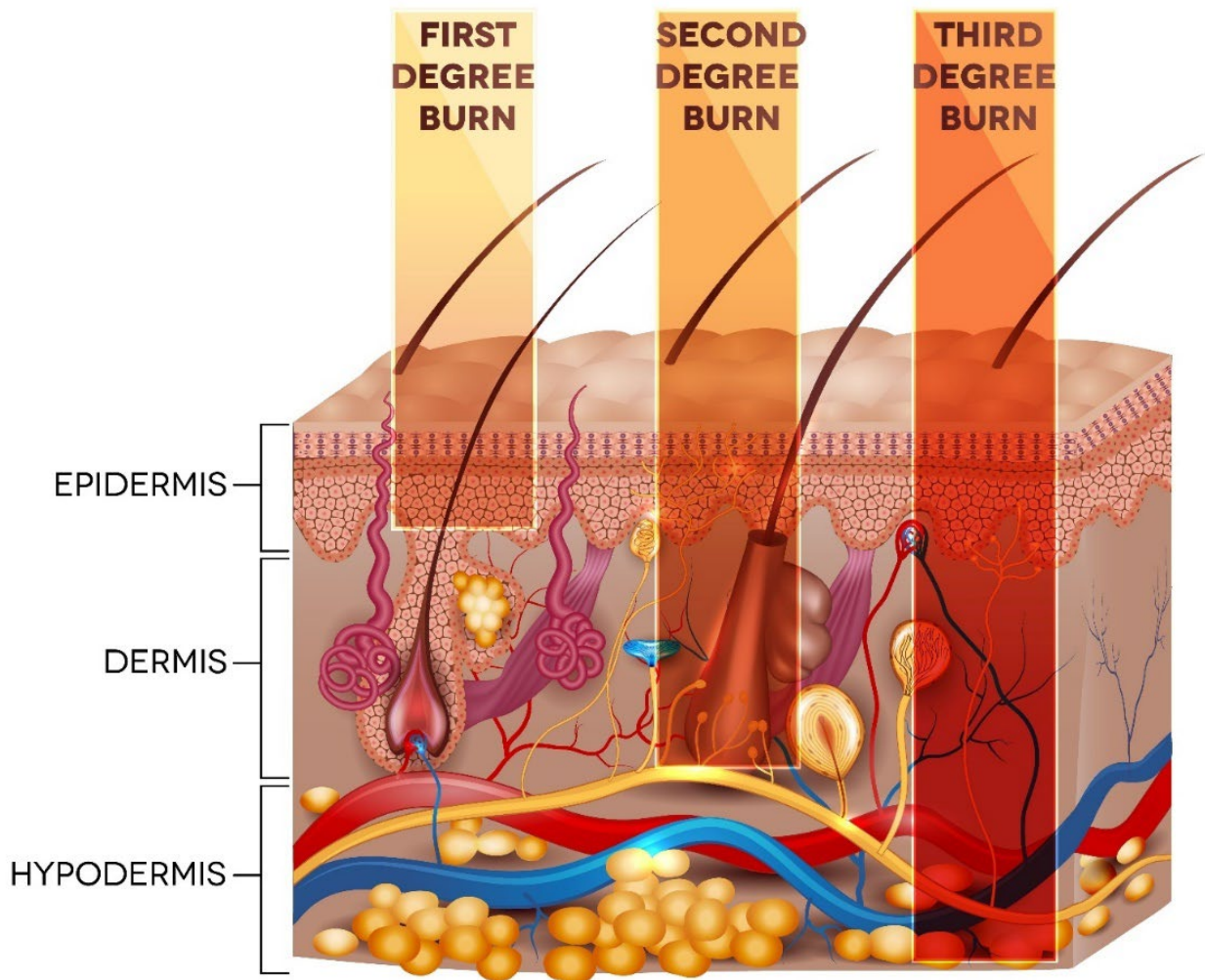


Second degree burn injury

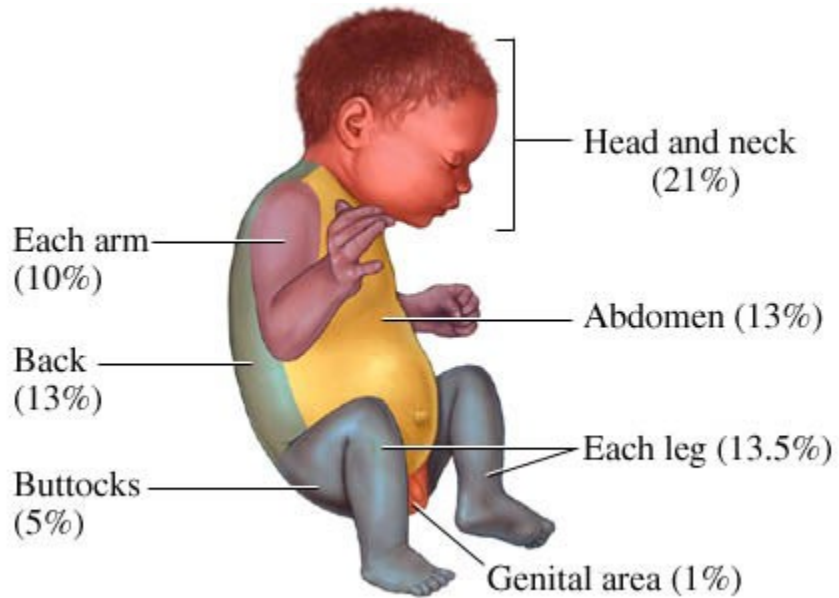
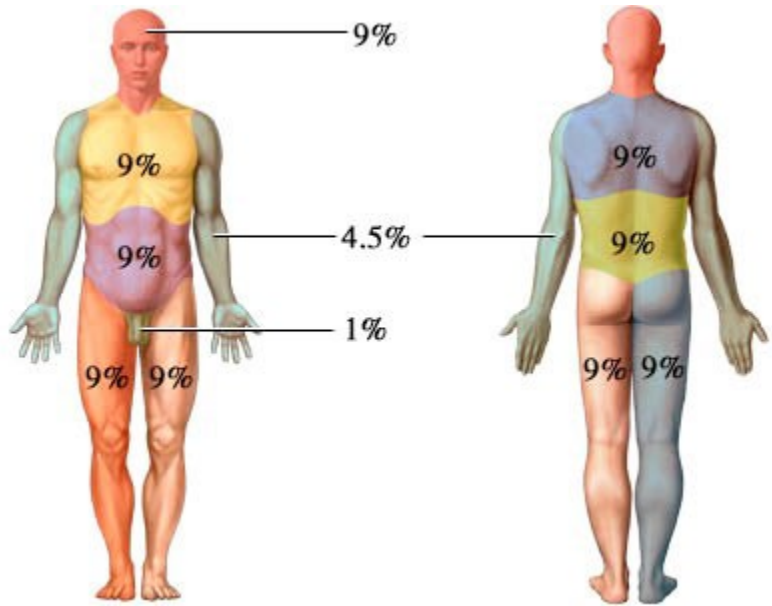


Third degree burn injury





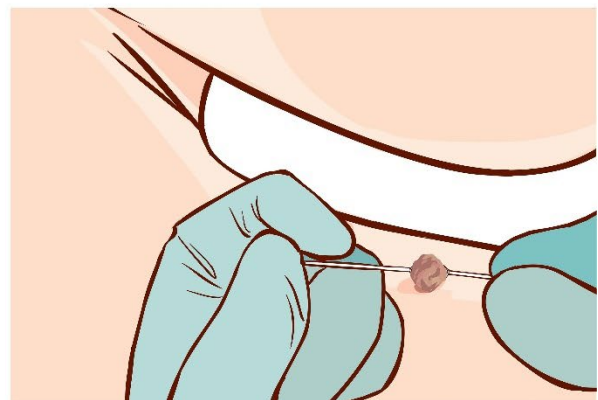
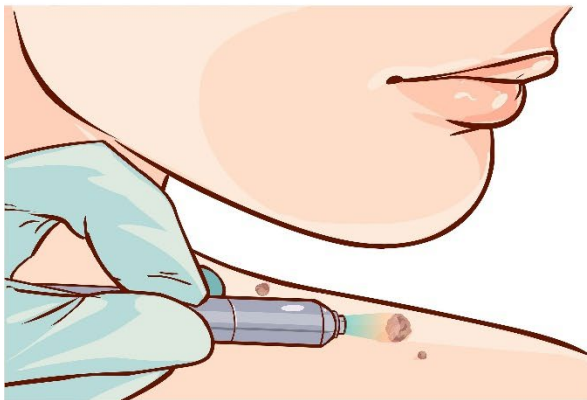
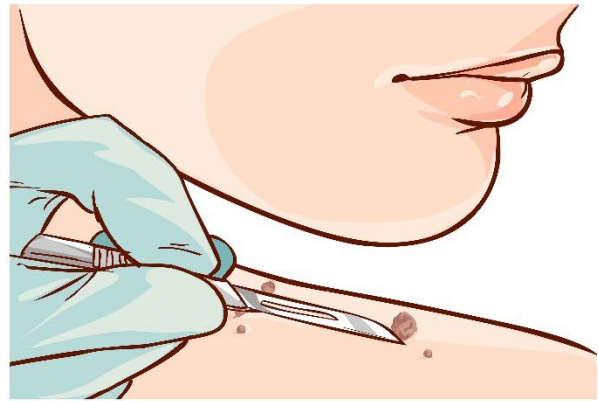
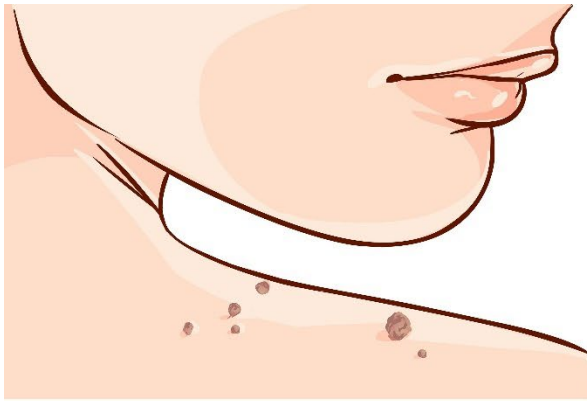
Rule of Nines (Adult vs Infant)



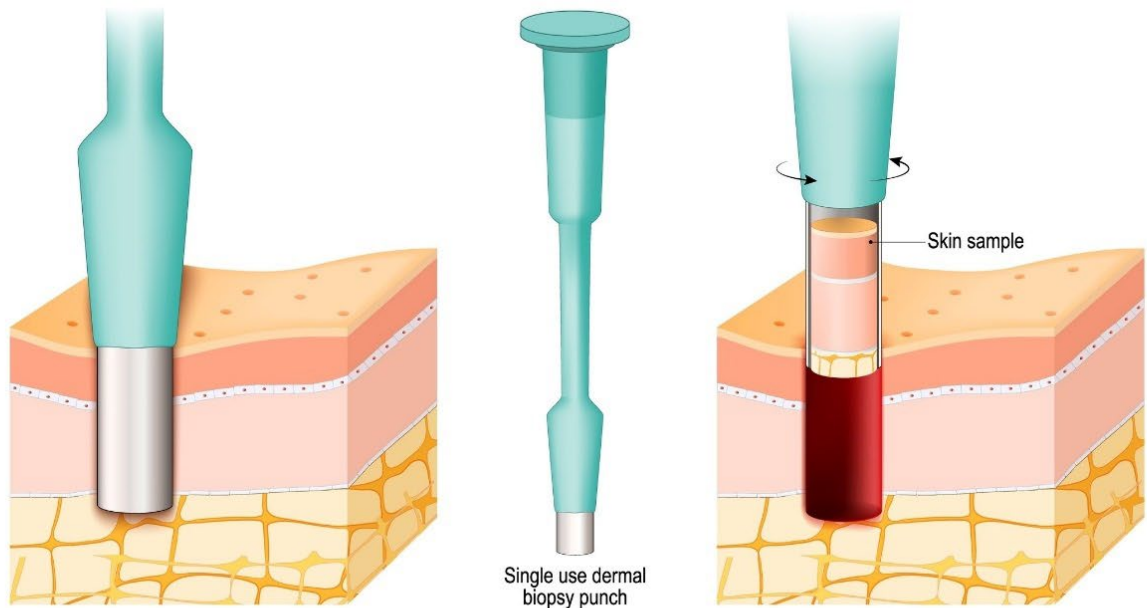
Skin Tag Removal

In the CPT® Index look for Skin/Tags/Removal and you are directed to codes 11200, 11201. Code selection is based on the number of skin tags removed.

In the ICD-10-CM Alphabetic Index look for Tag/skin and you are directed to L91.8. Verify code selection in the Tabular List.

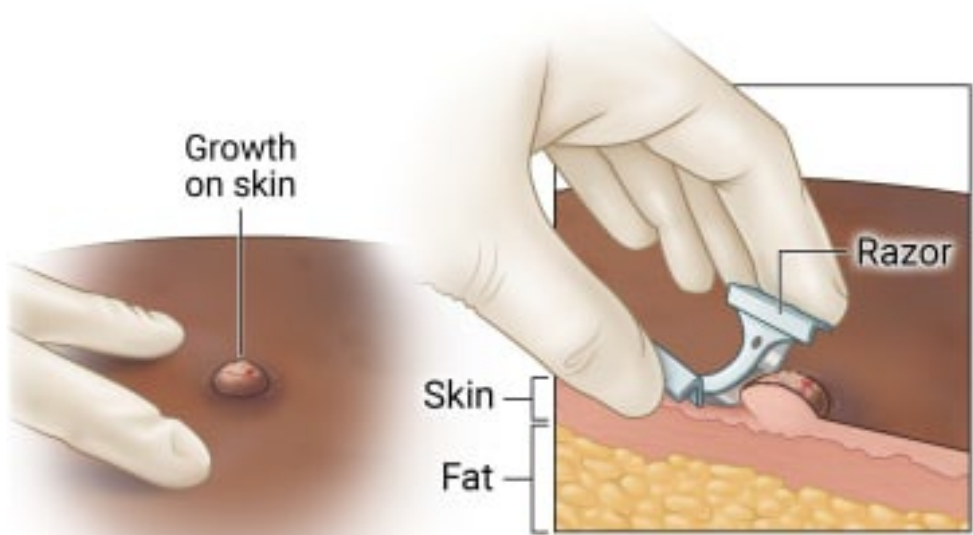
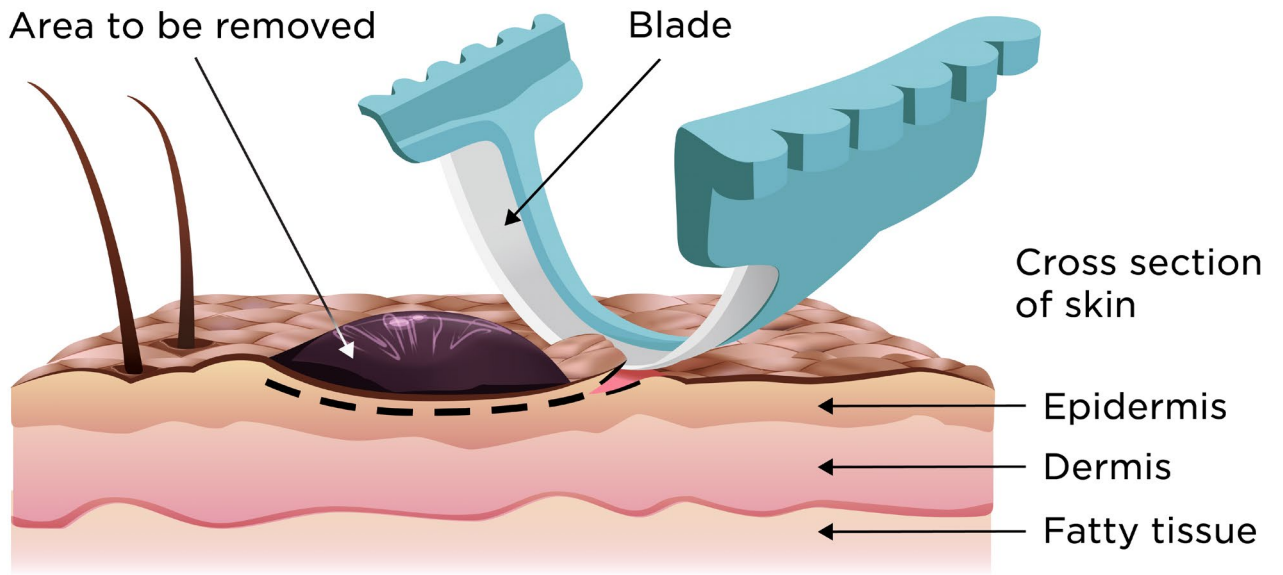


Skin biopsy

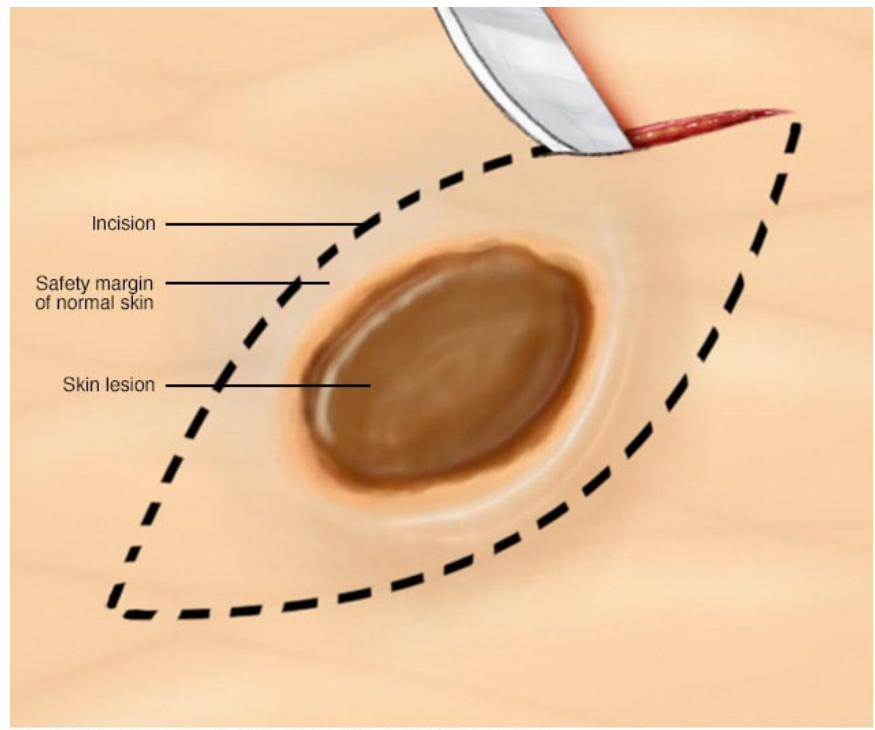
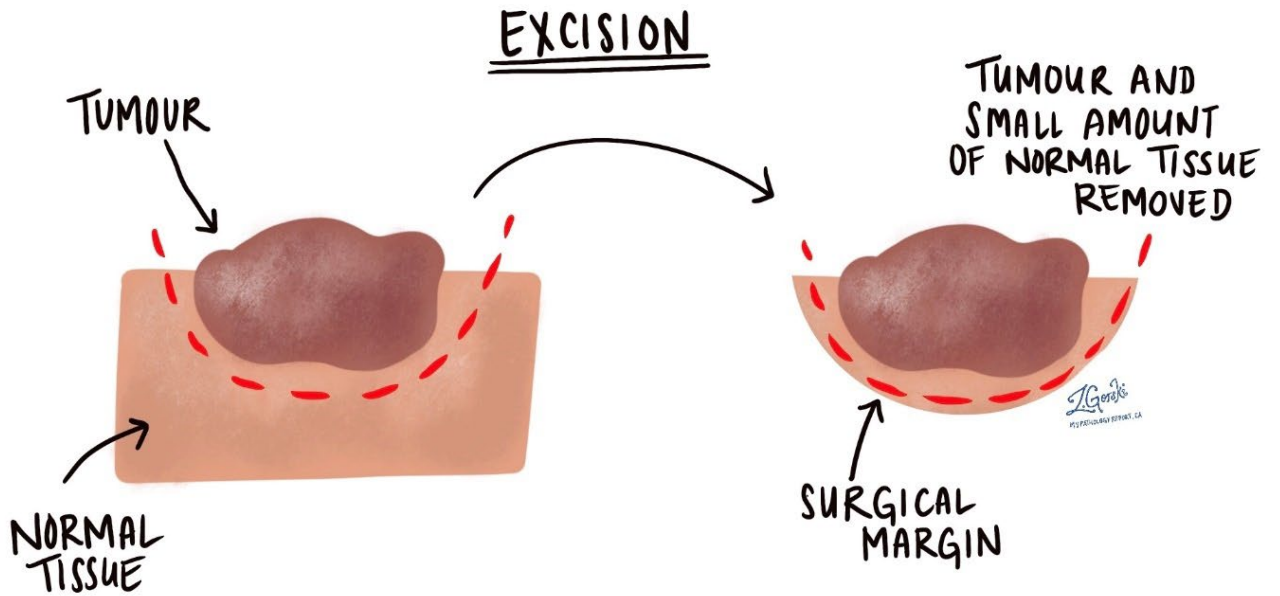


PUNCH BIOPSY

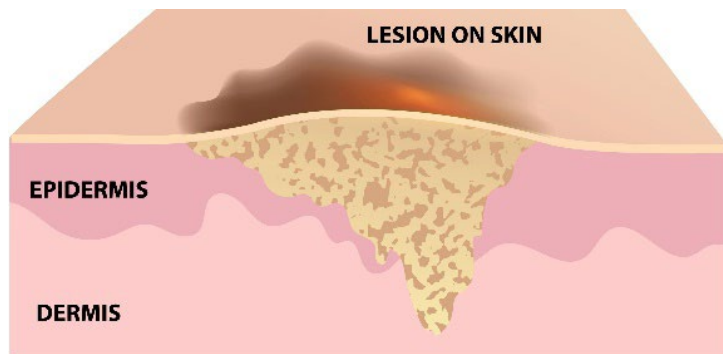
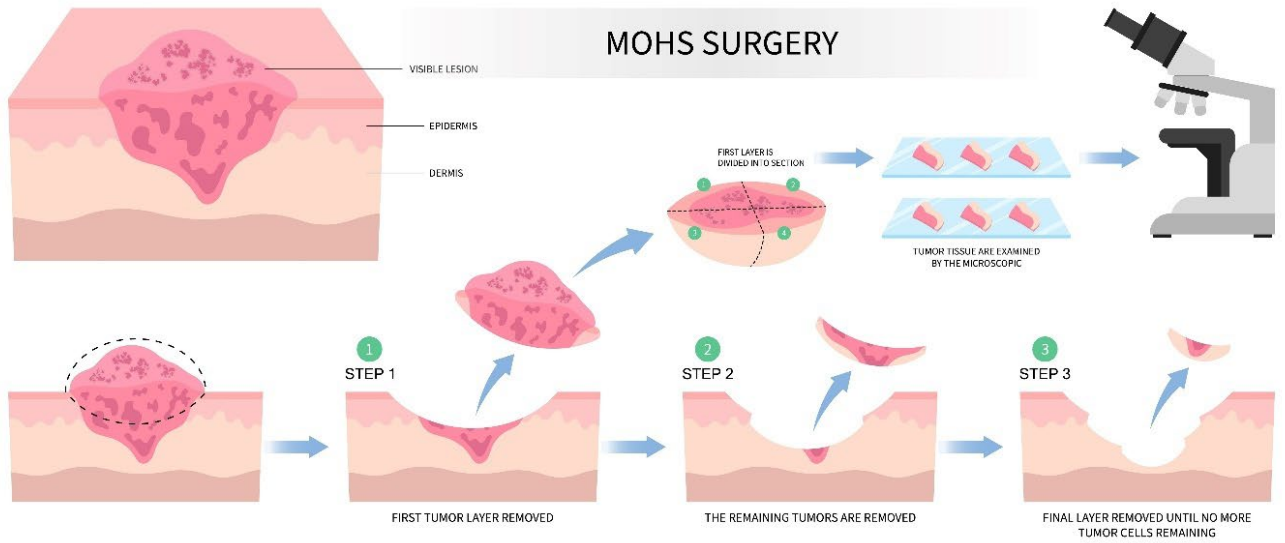
Skin Shave Biopsy



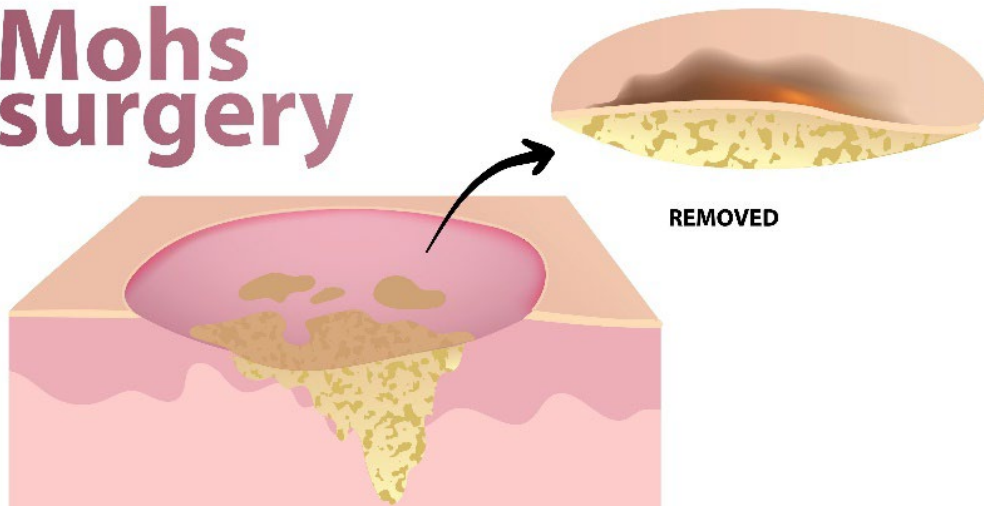
© 2023 Healthwise



© MAYO FOUNDATION FOR MEDICAL EDUCATION AND RESEARCH. ALL RIGHTS RESERVED.

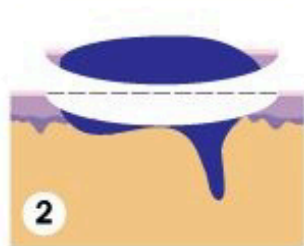


Mohs surgery

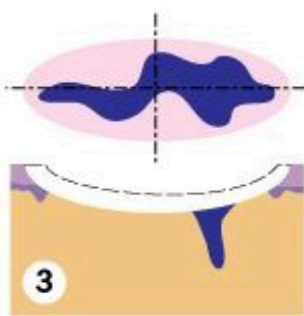




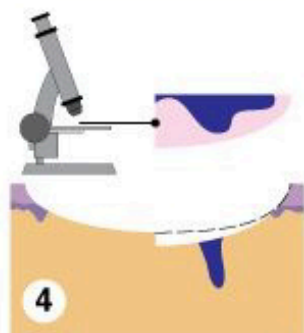
Step 1: The roots of a skin cancer may extend beyond the visible portion of a tumour. If these roots are not removed, the cancer will recur



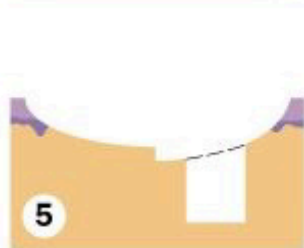
Step 2: The visible portion of the tumour is surgically removed



Step 3: A layer of skin is removed and divided into sections. The ACMS surgeon then colour-codes each of these sections with dyes and makes reference marks on the skin to show the source of these sections. A map of the surgical site is then drawn



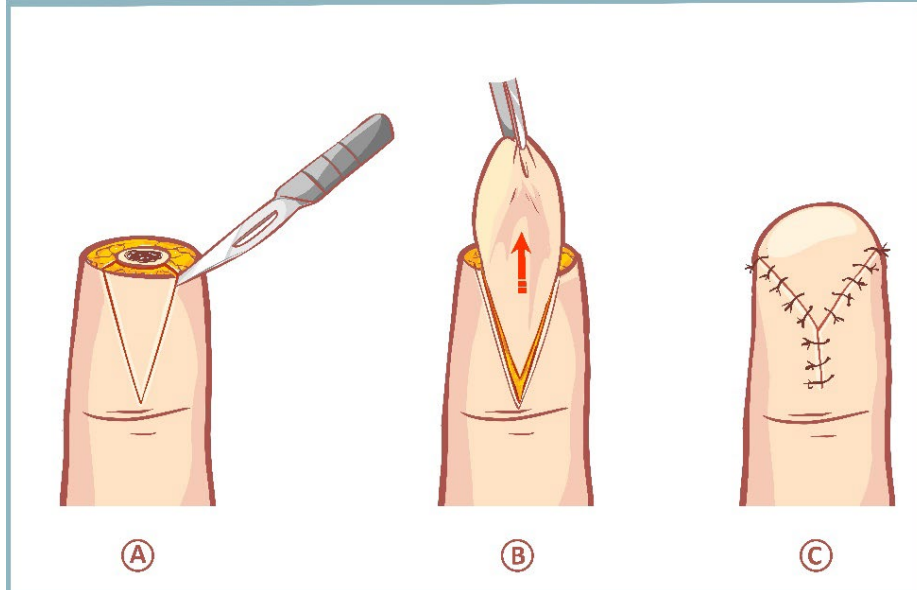
Step 4: The undersurface and edges of each section are microscopically examined for evidence of remaining cancer



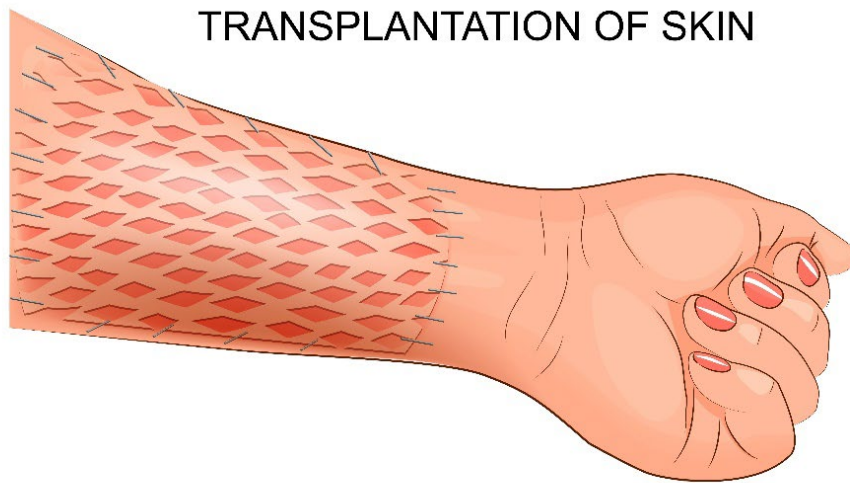
Step 5: If cancer cells are found under the microscope, the ACMS surgeon marks their location onto the “map” and returns to the patient to remove another layer of skin – but only from precisely where the cancer cells remain

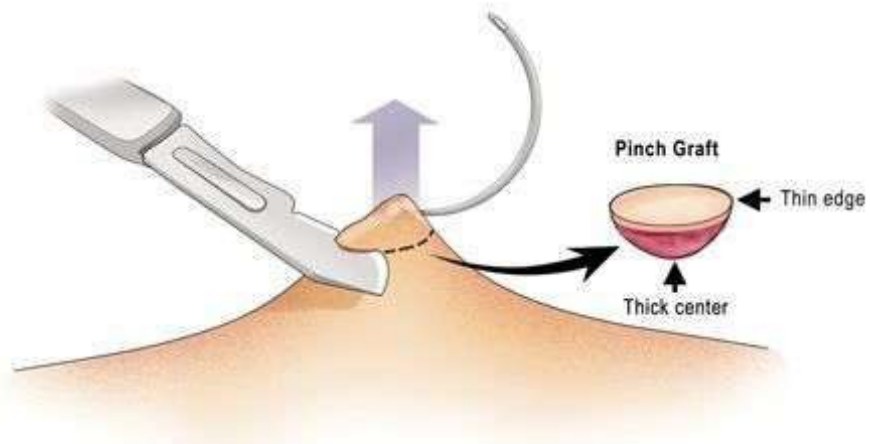
Step 6: The removal process stops when there is no longer any evidence of cancer remaining in the surgical site. Because Mohs surgery removes only tissue containing cancer, it ensures that the maximum amount of healthy tissue is kept intact

V-Y Advancement Flap

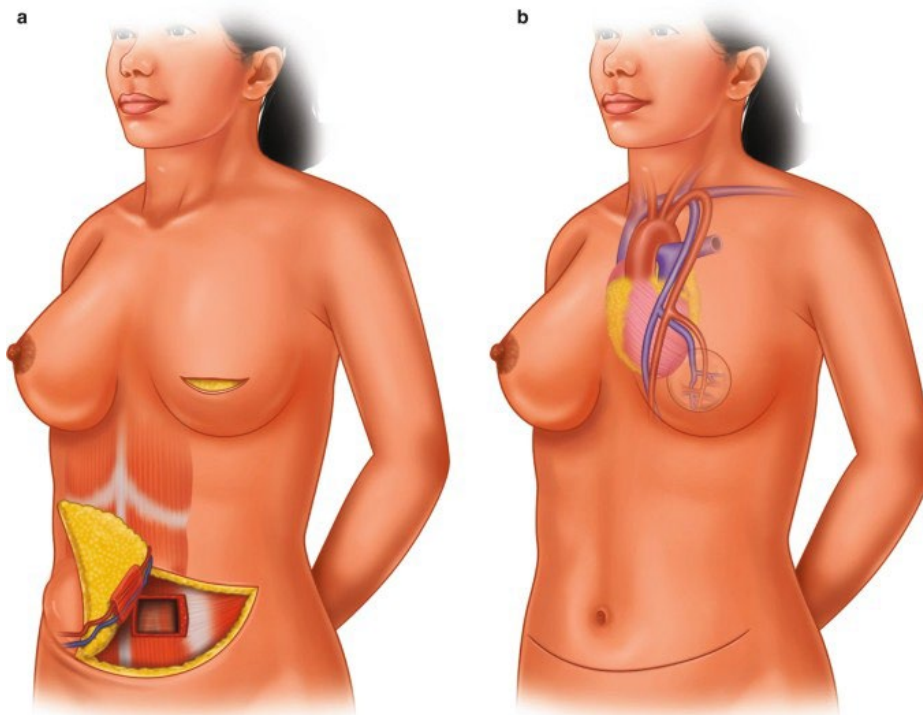


TRANSPLANTATION OF SKIN

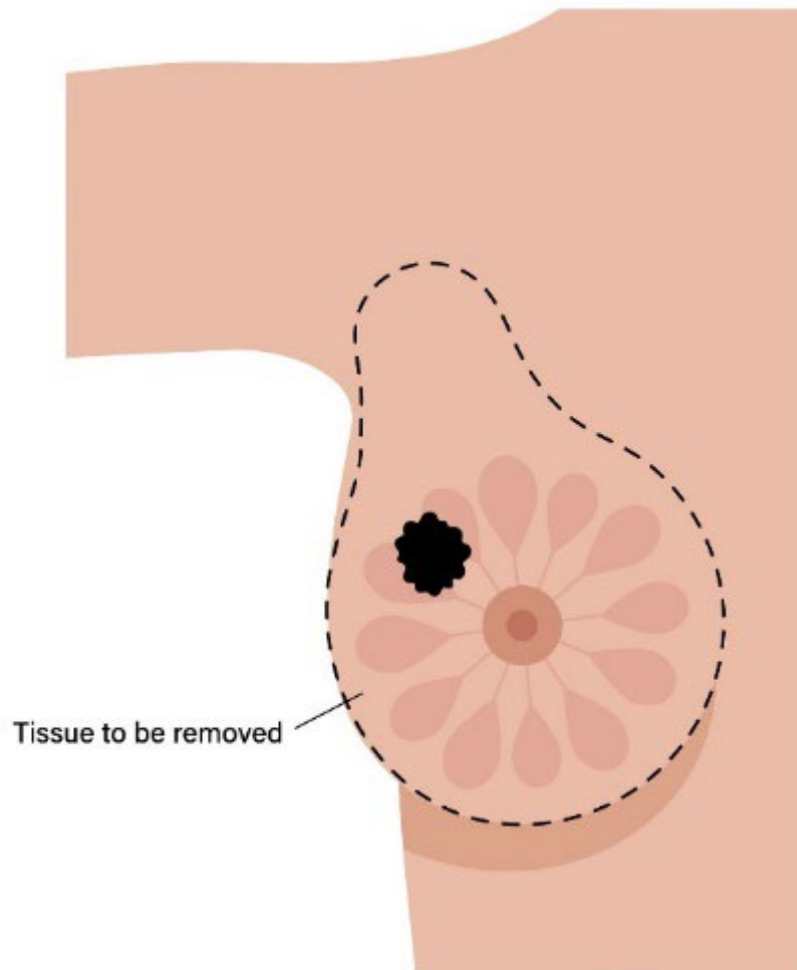


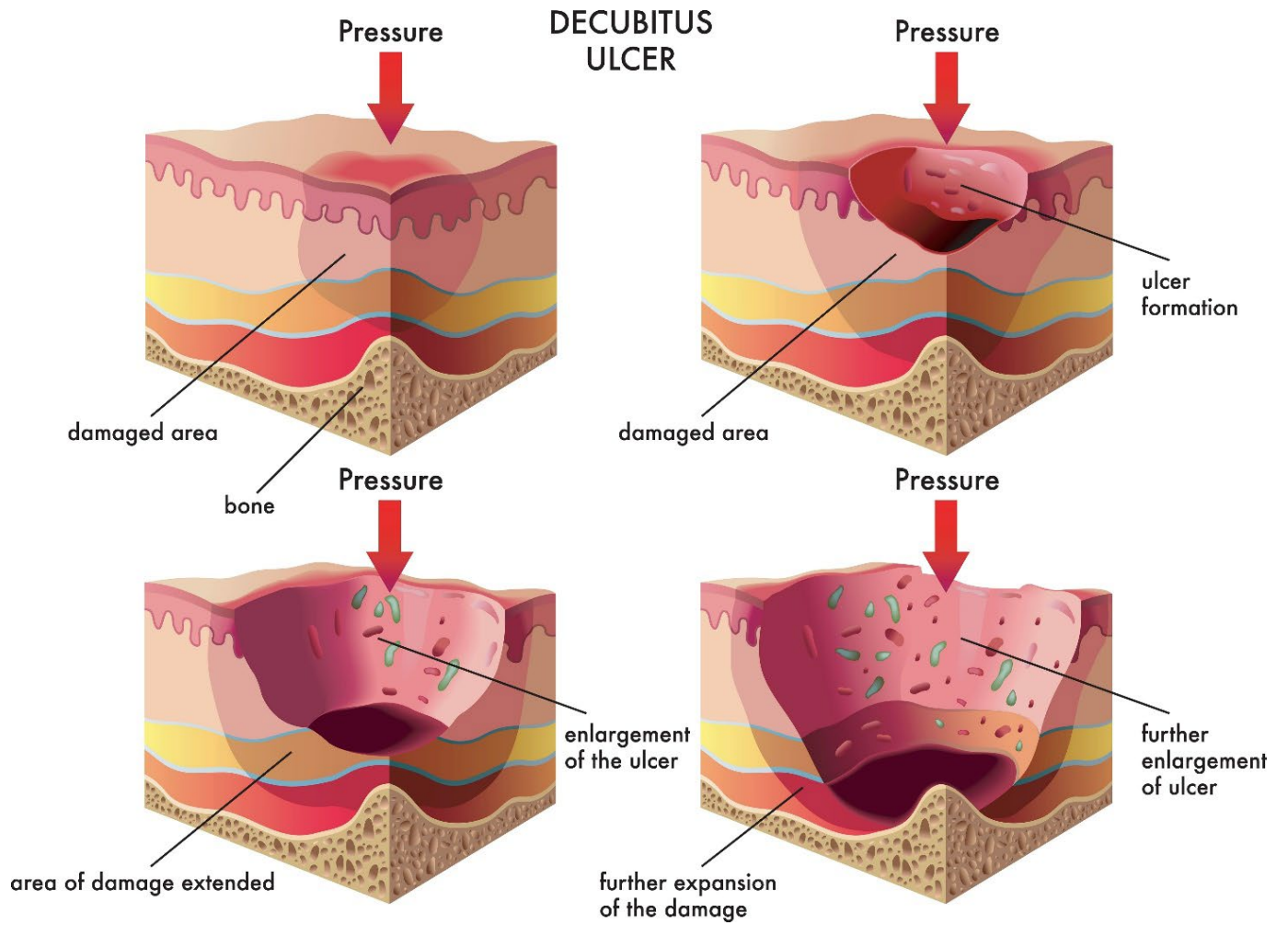


TRAM is a transverse rectus abdominis myocutaneous flap method of breast reconstruction. For the TRAM flap, in the CPT® Index, look for TRAM Flap/Breast Reconstruction and you are directed to codes 19367-19369.



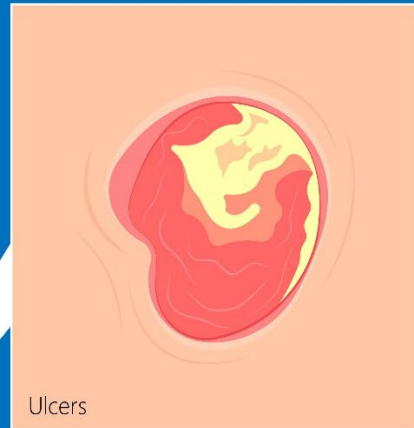
RADICAL MASTECTOMY



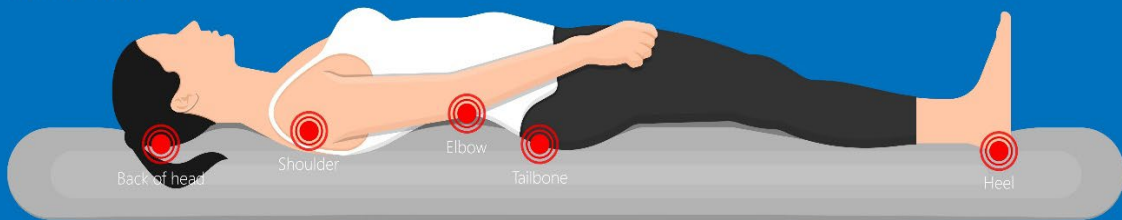

Bedsore (Pressure Ulcers)

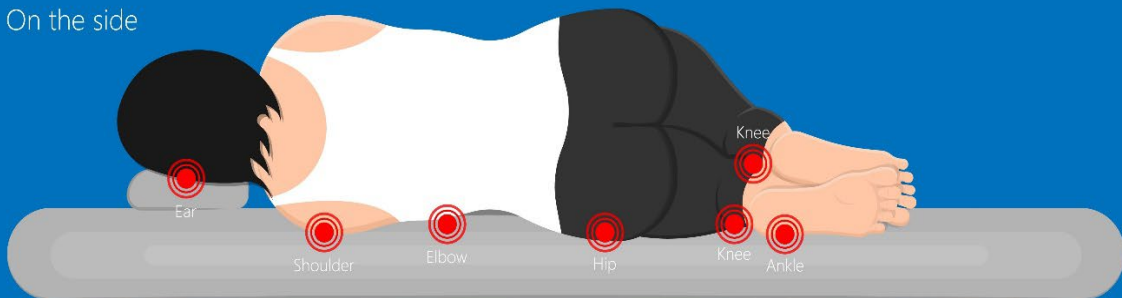
Injuries of the skin and underlying tissue resulting from prolonged pressure on the skin

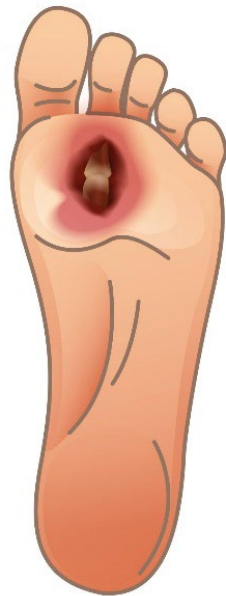
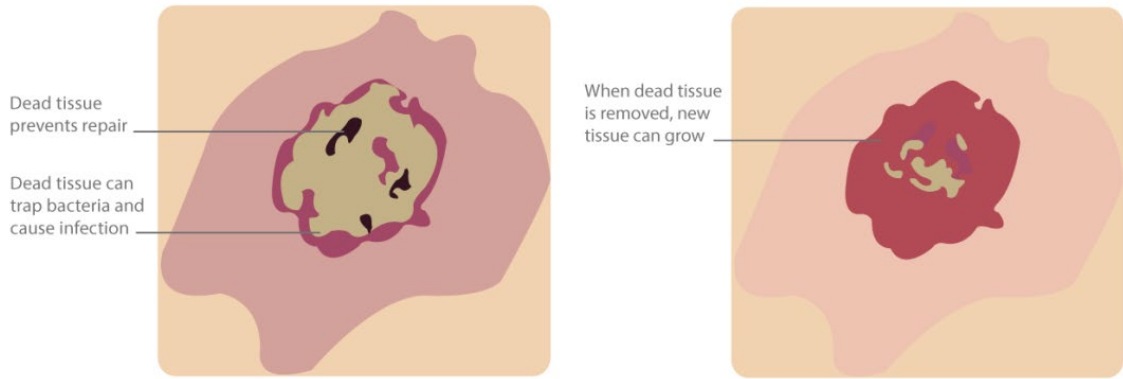
On the back



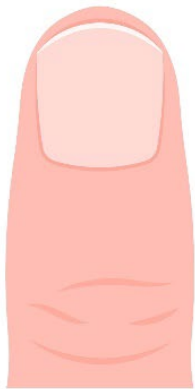On the side



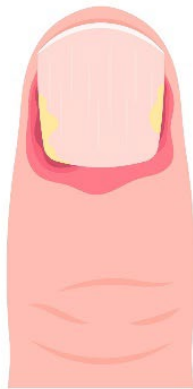

DIABETIC FOOT

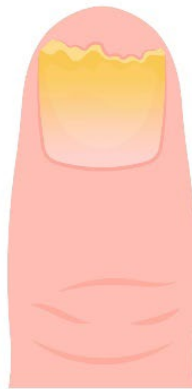NAIL DISEASES



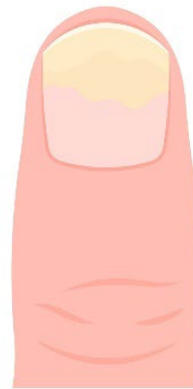HEALTHY NAIL



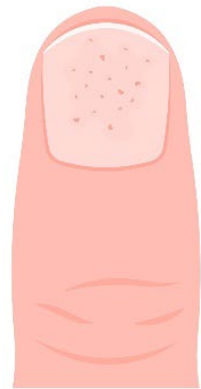PARONYCHIA



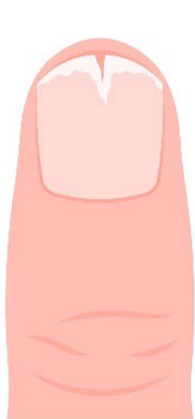
ONYCHOMYCOSIS



ONYCHOLYSIS



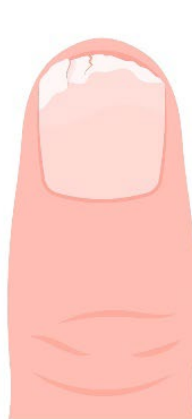
NAIL PITTING



ONYCHOSCHIZIA



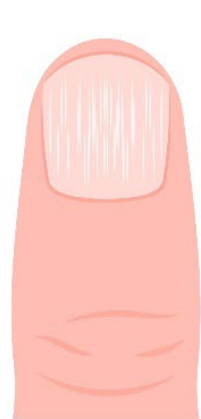ONYCHOGRYPHOSIS



BRITTLE NAILS

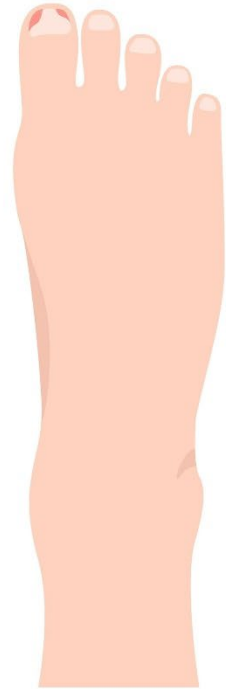

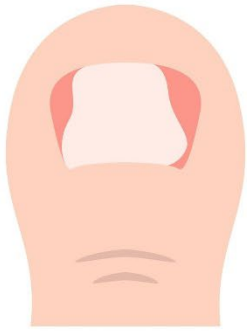


LEUKONYCHIA



RIDGES ON NAILS

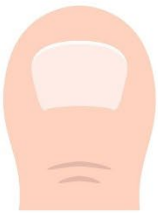NAIL DISEASES
INGROWN TOENAIL
onychocryptosis



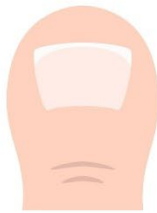NAIL CLIPPING

MATRIXECTOMY

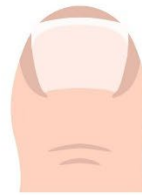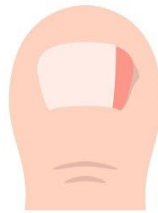VANDENBOS
PROCEDURE

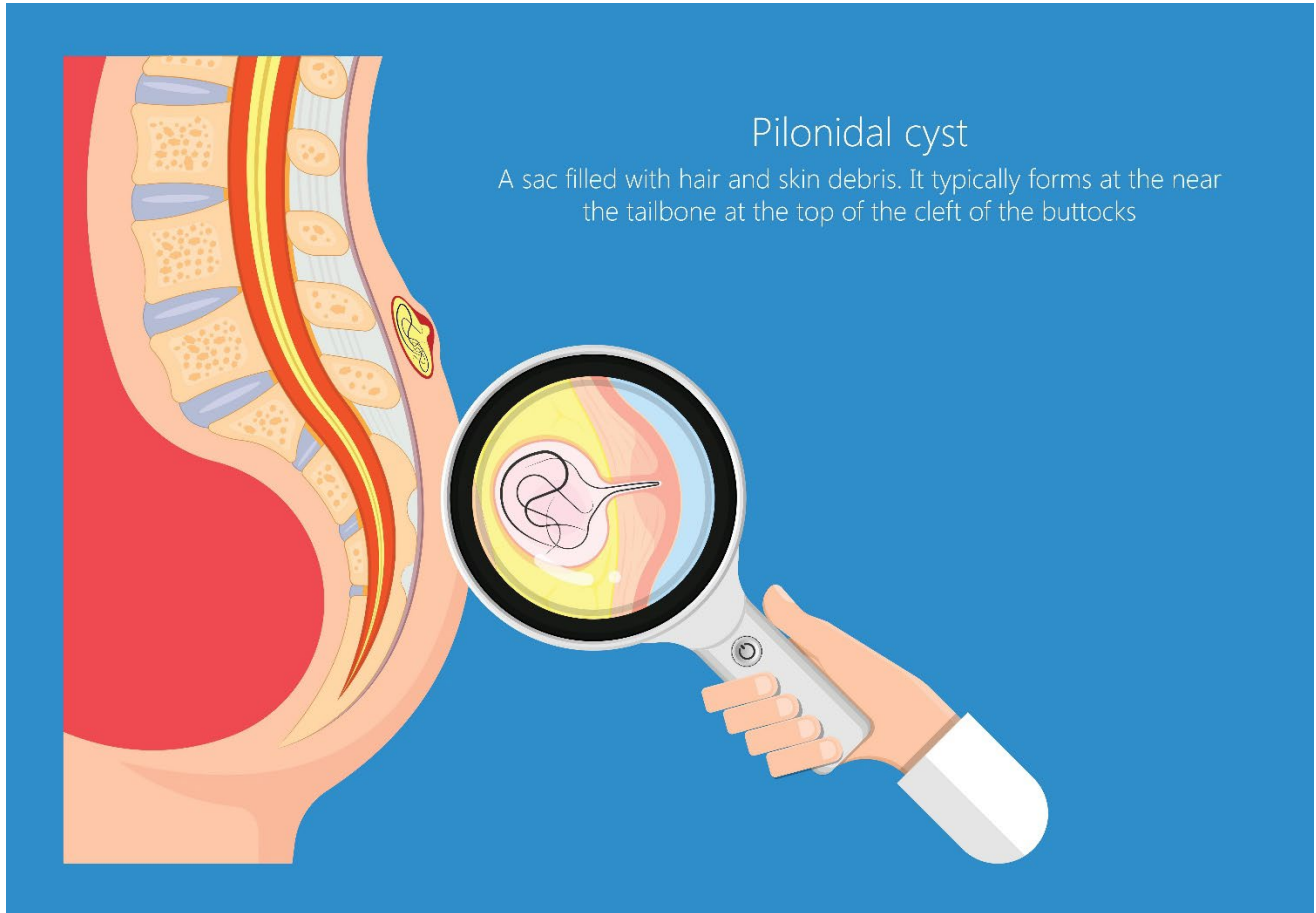


wrong



right

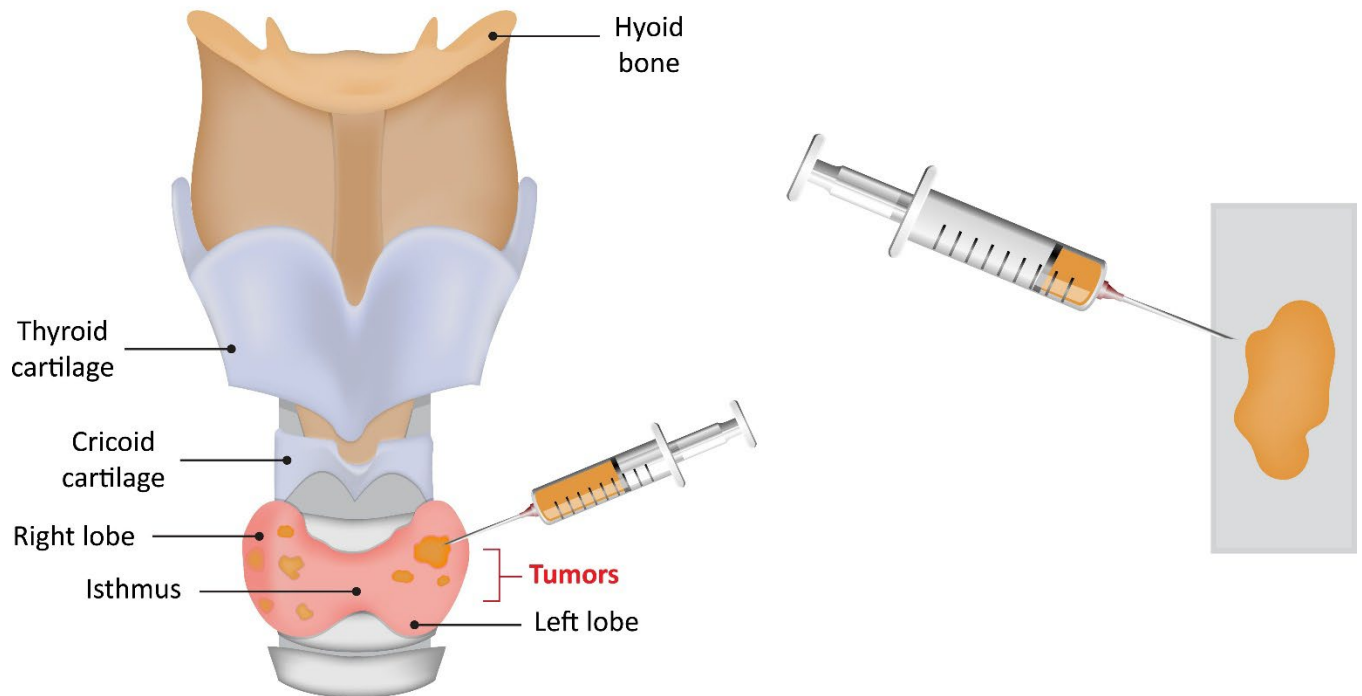


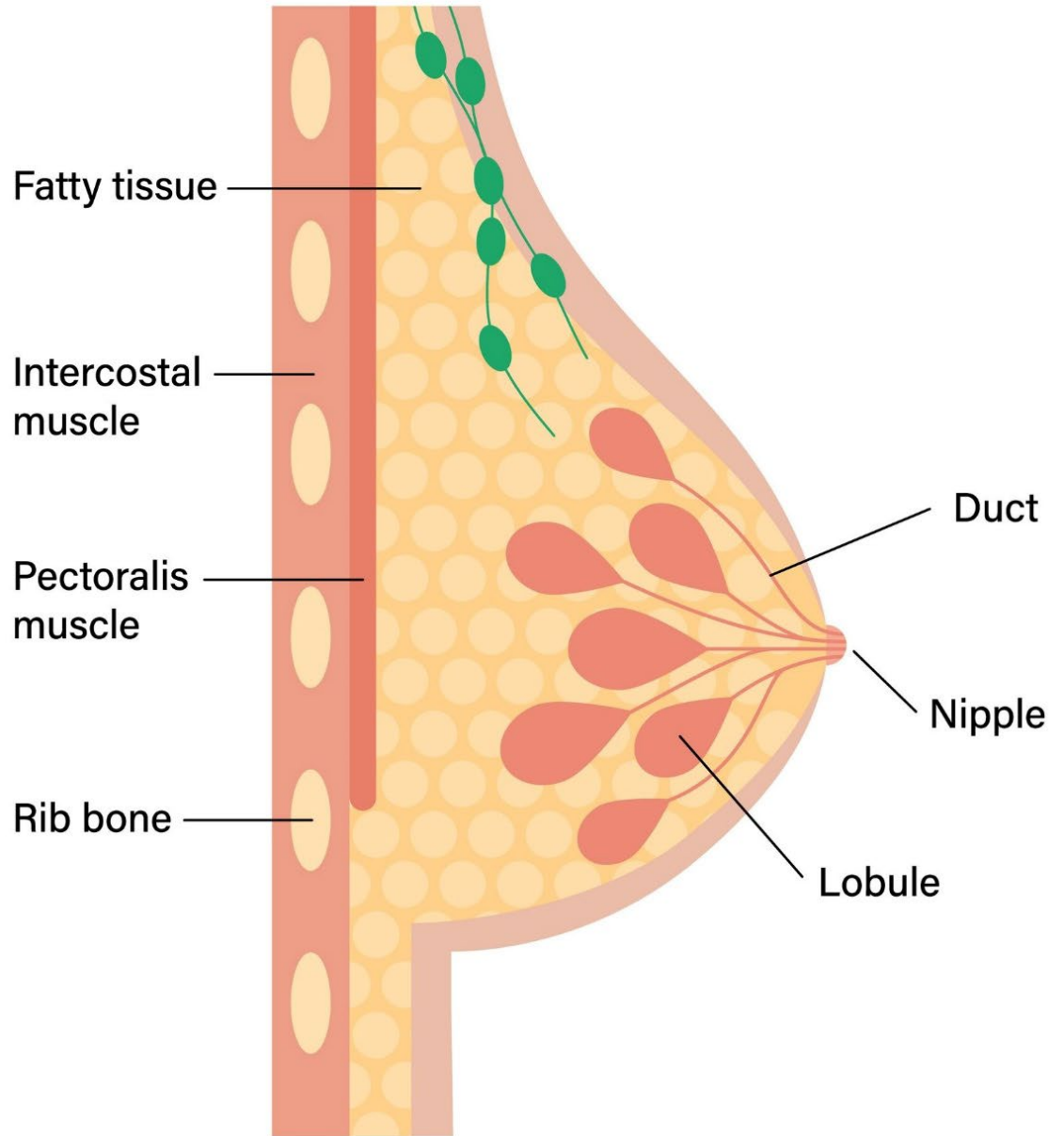


Pilonidal cyst

A sac filled with hair and skin debris. It typically forms at the near the tailbone at the top of the cleft of the buttocks

Fine Needle Aspiration of Thyroid Nodules





DISEASE FEMALE BREAST

